TOSHIBA
Leading Innovation

Aquilion® ONE:
Pediatric Imaging

Richard Mather, PhD

Senior Manager, CT Clinical Science
Toshiba America Medical Systems, Inc.

The use of CT in pediatric diagnostic procedures has increased significantly over the past decade. New advanced applications along with faster scan times and submillimeter, isotropic resolution have made CT a valuable and potentially life saving diagnostic tool. Each year, there are more than 7 million pediatric CT procedures performed in the United States[1]. While this means that a great number of children's lives are positively impacted by CT imaging each year, it also means that it is essential to consider the risks associated with medical imaging. For pediatric imaging, the two principle risks are radiation exposure and sedation complications. With 16 cm of craniocaudal coverage in a single axial rotation, Toshiba's Aquilion ONE CT scanner is uniquely suited to minimize both of these risks.

UNIQUE IMAGING REQUIREMENTS

There are anatomical and physiological differences between children and adults that make pediatric imaging a uniquely challenging endeavor. Anatomical differences such as lower bone density, smaller vessels, and significantly less fat surrounding their organs create different image quality requirements. Dynamic factors such as high heart rates, difficulty holding their breath, and crying during the exam can also make imaging a challenge. For example, since the natural contrast provided by intra-abdominal fat in adults is reduced in pediatric patients, the images generally require more signal to noise compared to adult images. This is somewhat mitigated by the fact that most pediatric patients are smaller and less attenuating than adults, so their images are naturally lower in noise. All these complex factors make it essential that the kV and mA techniques used for pediatric patients are tailored to their unique imaging needs and body sizes. Tailoring the kV and mA is especially important since children are more sensitive to radiation than adults. The BEIR VII report, the main authority on the health risks from low levels of ionizing radiation, shows that the risk from radiation exposure increases rapidly with decreasing age[2]. In order to minimize the risks to children, it is critical that the appropriate exposure is used on each individual child.

Radiation, however, is not the only risk to a pediatric patient undergoing a CT exam. Because helical CT scans last for several seconds and are sensitive to patient motion, it is often necessary to sedate children to ensure an adequate study and prevent the added radiation of a rescan should the study prove non-diagnostic. While the use of sedation varies from practice to practice, one national survey of sedation use in pediatric imaging reported that over 55% of all pediatric CT exams used some form of light or deep sedation. Furthermore, a more recent study of complications in pediatric sedation found that adverse events occurred in 3.3% of cases and unplanned treatments were necessary in 1.1% of cases[3]. Even though the incidence of adverse events is low, the researchers at the Dartmouth Pediatric Sedation Project Site "firmly believe that sedation represents an area of pediatric care that exposes patients to the greatest risk of iatrogenic morbidity and mortality"[4]. In order to minimize the risk to pediatric patients, it is necessary to not only lower the radiation dose but also to minimize the need for sedation.

IMAGE GENTLY℠

Concerned about awareness of CT radiation dose among both parents and medical professionals, the Alliance for Radiation Safety in Pediatric imaging was formed within the Society of Pediatric Radiology (SPR) in late 2006. This group grew to

include radiologists (ACR), technologists (ASRT), and medical physicists (AAPM) and started a campaign known as Image Gently. The purpose of this campaign is to increase awareness about radiation dose in pediatric imaging and to promote best practices for effective dose reduction. The campaign has gained international awareness within the imaging community and among imaging manufacturers. Toshiba and others are working with the Image Gently campaign to continue educational efforts of our applications staff and users as well as to continue optimizing our scanners to produce high quality images at the lowest possible radiation dose.

The most effective method of dose reduction for pediatric patients is to limit the scans to only those that are appropriate. The Image Gently campaign urges clinicians to use only single phase scans whenever possible as pre- and post-contrast and delayed scans "rarely add additional information in children" but can contribute to doubling and tripling the radiation dose[5]. Furthermore, it is always important to ensure that the CT scan is the appropriate diagnostic test for the clinical question at hand. Finally, eliminating the need for rescans due to patient motion is critical. To this end, many sites employ sedation to minimize movement during the scan acquisition. Therefore, in order to reduce the overall examination risk to pediatric patients, techniques should be employed to minimize radiation exposure, potential rescans, and sedation.

TOSHIBA PEDIATRIC DOSE REDUCTION

Toshiba's commitment to patient centered imaging and support of the Image Gently campaign mandate continuous development in technologies that enhance patient safety through radiation dose reduction and avoiding sedation. In order to use the appropriate radiation dose for the appropriate patient, automated software such as SUREExposure Pediatric measures the size and attenuation of each patient and tailors the radiation dose to achieve the necessary image quality for the task at hand. Using an automatic,

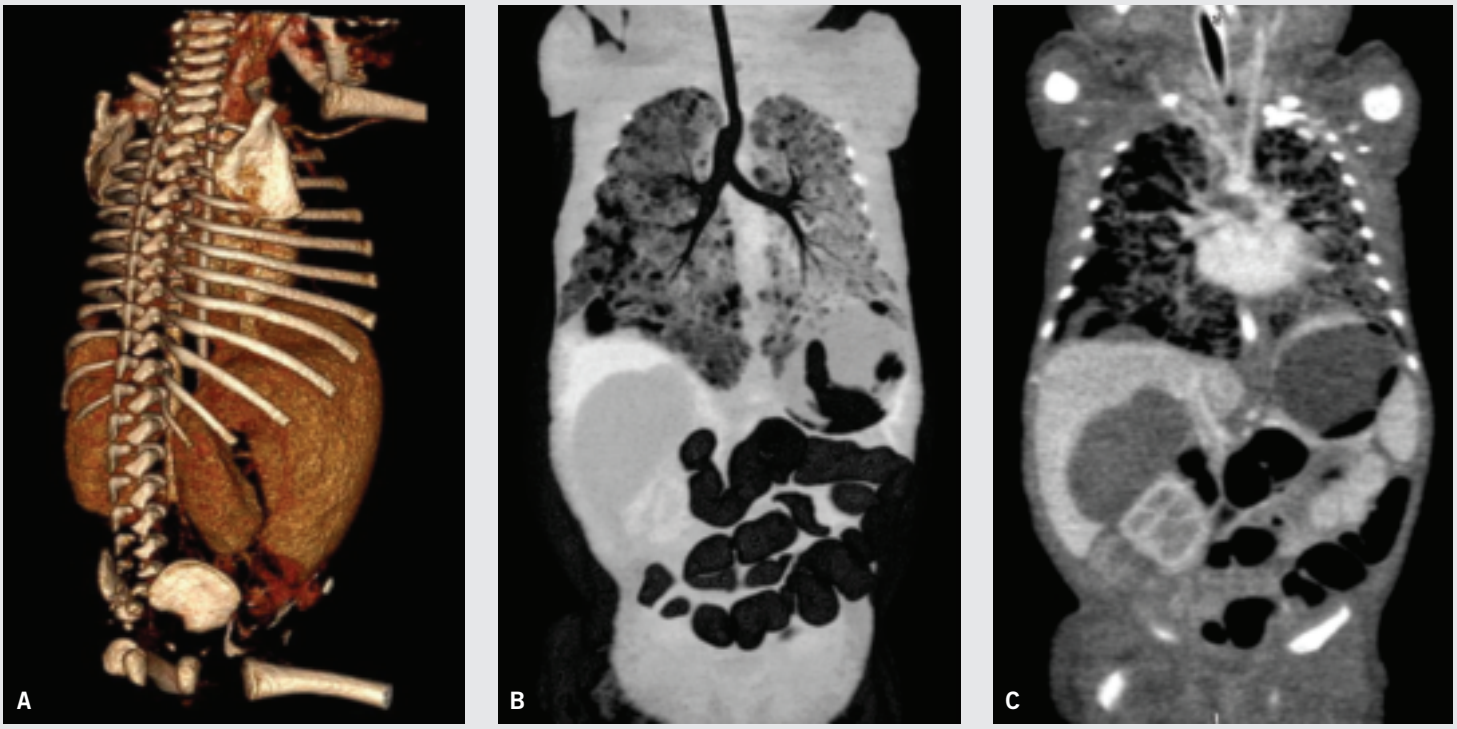

Figures 1A, B & C: These images represent the exam of a 2-week-old infant scanned with the Aquilion ONE. With 16 cm of volume coverage, the entire chest and abdomen were covered in a single 0.5 second rotation using just 15 mAs and 0.44 mSv of dose, and no sedation. The panels show the 3DVR, coronal MinIP, and coronal MIP reconstructions demonstrating diffuse lung infiltration and abdominal distension. *Images courtesy of Charité Hospital Humboldt University, Berlin.*

individualized protocol maintains a uniform level of image quality for every patient while ensuring that the minimum dose necessary to achieve that quality is used.

SUREExposure Pediatric starts working from the point at which the patient is registered. Monitoring the patient's age during the registration process, the software automatically takes the operator to the Aquilion's optimized suite of pediatric protocols. For each clinical task, there is a separate set of protocols that are tailored to the task's diagnostic needs. For example, a protocol for estimating liver size can handle a significant amount of image noise and would have SUREExposure settings that reflect that: a high target noise value and a low maximum mA. On the other hand, a protocol set up to characterize a liver lesion requires more radiation dose to ensure a high contrast to noise ratio. Finally, each of these task-oriented protocols is further refined by patient weight with slightly different noise targets and upper and lower mA limits. Protocol tailoring optimizes the radiation dose for patients of every size and automates the protocol guidelines defined by the Image Gently campaign.

Toshiba's Aquilion ONE dynamic volume CT scanner goes one step further in pediatric dose reduction. With 16 cm of craniocaudal coverage in a single axial rotation, the Aquilion ONE can scan most infant's and toddler's chests or abdomens in one rotation and no table motion. Since this eliminates the need for helical overlap and over-scanning, it further minimizes the radiation dose for most pediatric cases. In comparing an axial volume acquisition to a helical scan over 16 cm, and equalizing the noise between the two scans, there is a dose savings of 30% when using the volume acquisition. By using volume scanning, when appropriate, the radiation risk to pediatric patients can be minimized with no loss of image quality.

TOTAL RISK REDUCTION

As described earlier, however, the risk to pediatric patients does not come solely

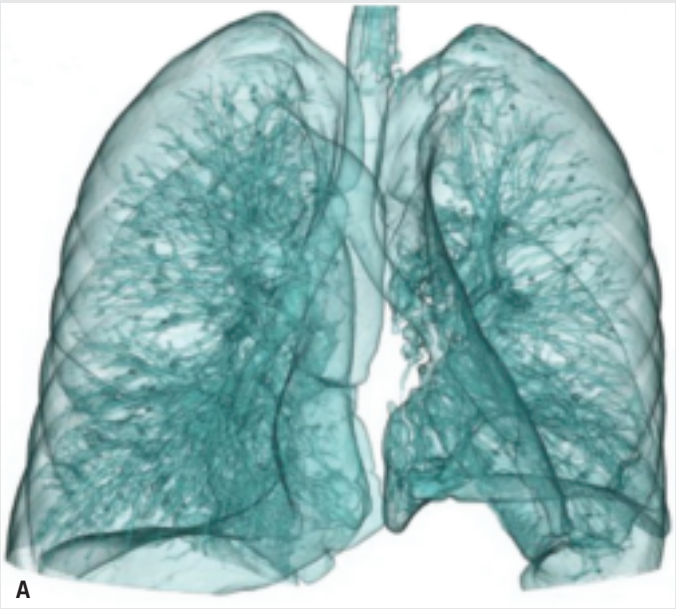

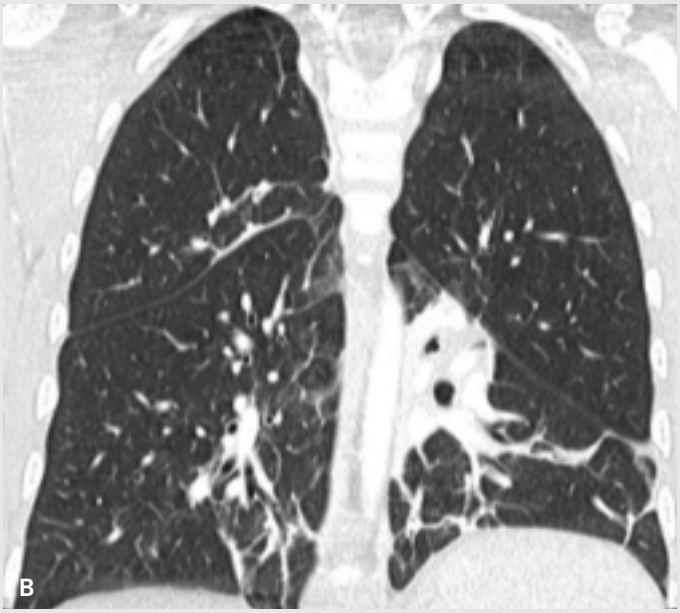

Figure 2A & B: 3DVR and coronal high resolution lung views show mild patchy atelectasis in the right lower lobe and along the right major fissure of the right upper lung lobe, the left lung shows consolidation in the lower lobe and a dilatation of the bronchus. Volume scan mode used with one 0.35 second rotation and 0.4 mSv of dose, without sedation. *Images courtesy of Arkansas Children's Hospital.*

from radiation exposure. Since many young patients have trouble staying completely still, a clinician has to choose between using sedation and running the risk of a non-diagnostic exam. With 16 cm volume scanning on the Aquilion ONE, sedation can be greatly reduced or possibly eliminated since an entire acquisition can be accomplished more than 10 times faster than helical, in as little as 0.35 seconds, and motion during the scan can be eliminated. Figure 3 shows the chest CTA of a 2-year-old patient with a congenital pulmonary sling. Even though this patient was breathing and crying during the examination, the scan was completed without sedation using a single 0.35 second volume rotation. With the rapid, whole volume acquisition of the Aquilion ONE, this study has no motion artifact and was completed with a minimal risk to the patient.

Another inherent risk in using sedation with imaging procedures is that the sedation itself can alter the physiologic condition that is being examined. Sedation can cause relaxation of the airway in patients with tracheomalacia causing airway collapse. Once airway collapse occurs, extubation will be difficult. Additionally, in some cases, the use of sedation can be acutely dangerous to the patient. For example, patients with Williams Syndrome have been reported to undergo coronary artery collapse following anesthesia with a high risk of death. The ability to image these patients in one rapid rotation during free breathing can greatly minimize the overall examination risk.

Therefore, the reduction or elimination of anesthesia from a pediatric exam not only streamlines the scanning process but, more importantly, reduces the major contributor of acute risk to the patient. Furthermore, since volume scanning can be completed so quickly, sometimes during free breathing, the likelihood of needing a rescan, and extra radiation exposure, due to patient motion is drastically reduced. Finally, with the significant dose reduction possible on the Aquilion ONE, the overall

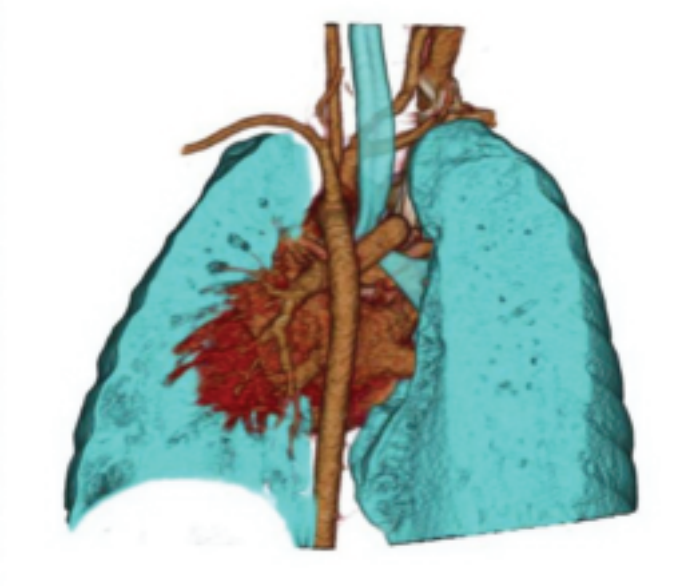

Figure 3: This image shows the 3D VR of a 2-year-old patient with a congenital pulmonary artery sling. The CT angiogram of the pulmonary artery was performed using just 7cc of iodinated contrast. The scan was acquired using a single 0.35 second rotation while the baby was breathing and crying. The total radiation dose of this exam was 0.4 mSv. *Image courtesy of University Of Florida Shands.*

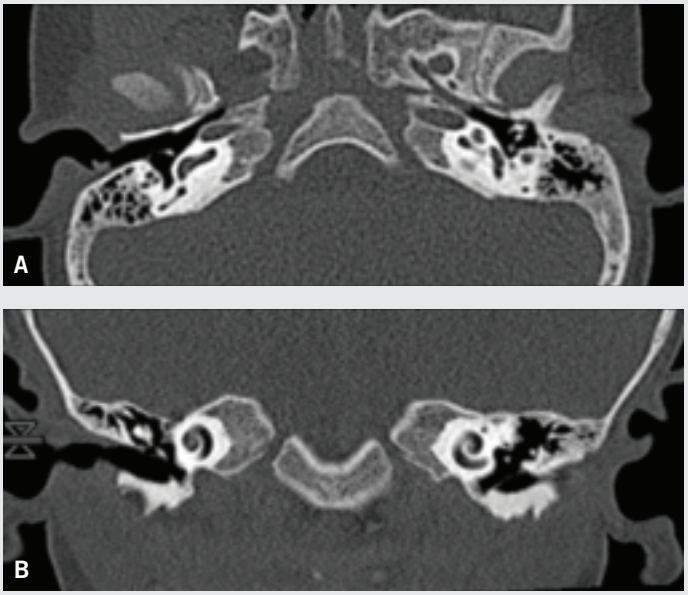

Figures 4A & B: The internal auditory canals of this 2-year-old patient were scanned for hearing loss. This high resolution scan was completed with a single 0.5 second volume acquisition and 0.22 mSv of dose and no sedation. From this scan, it was concluded that the patient has bilateral tympanic membrane thickening contributing to the hearing loss. Also, note the detail of the semi-circular canals. *Images courtesy of Arkansas Children's Hospital.*

acute and long term risk to the patient from the CT exam is minimized.

INITIAL EXPERIENCE AT ARKANSAS CHILDREN'S

Arkansas Children's Hospital (ACH) runs a busy pediatric CT service scanning over 30 patients per day. Long time advocates of radiation dose and sedation reduction in pediatric CT, ACH has kept on the cutting edge of CT technology. Continuing with this dedication to patient safety, ACH recently installed an Aquilion ONE in their Radiology department. Using the Aquilion ONE, ACH has scanned a wide variety of patients from sinus exams in a single rotation using 0.1 mSv of radiation dose to acquiring a whole 16 cm lung and chest in 0.35 seconds. Due to the rapid, volumetric imaging ability of the Aquilion ONE, their use of sedation has been significantly reduced for nearly all of their patients.

CONCLUSIONS

With advancing technology, the clinical utility of CT has increased significantly over recent years. This has led to a tremendous increase in the number of pediatric procedures and, therefore, in the total radiation exposure to the pediatric population. Furthermore, there is a distinct acute risk to pediatric patients from the use of sedation to ensure motion free studies using helical acquisitions. At cutting edge institutions around the world, the Aquilion ONE has proven its ability to dramatically reduce radiation dose and the use of sedation in pediatric patients. With its commitment to patient focused imaging, Toshiba has continuously developed technology to minimize patient risk.

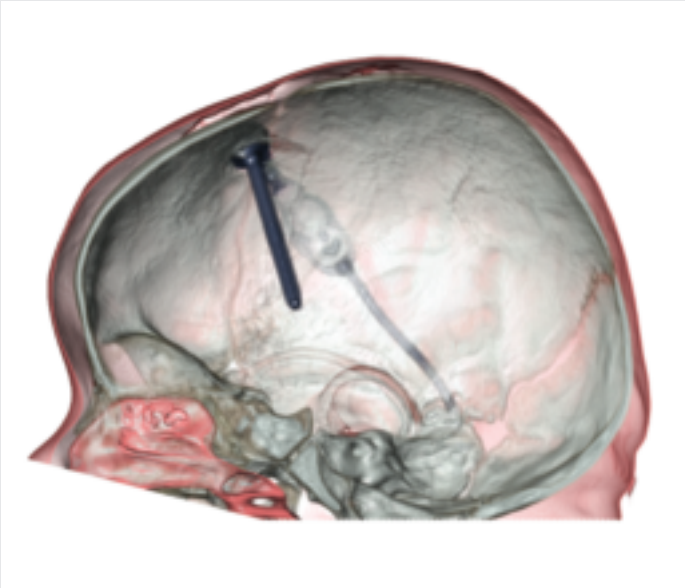

Figure 5: 3-year-old child with hydrocephalus and who has a ventricular shunt, showing signs of mental status changes likely due to increased intra cranial pressure. Patient is scanned using volume scan mode and 0.16 mSv of dose and no sedation to check placement and position of the right parietal shunt catheter. *Image courtesy of Arkansas Children's Hospital.*

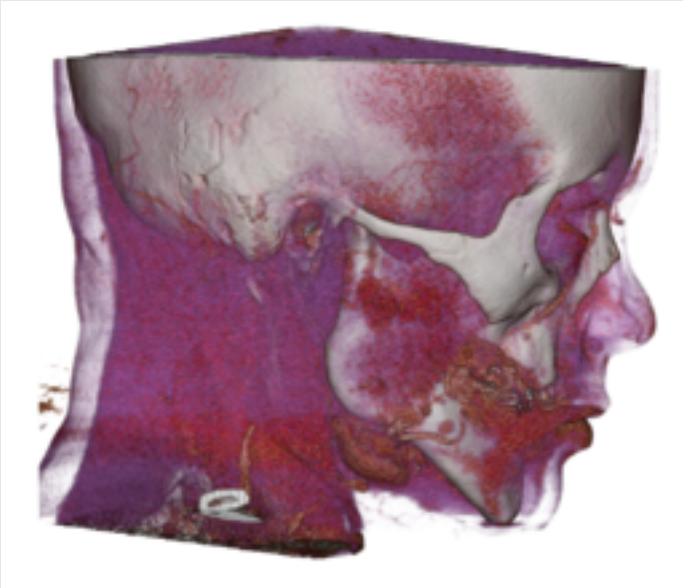

Figure 6: 8-year-old boy was diagnosed with lymphangioma and as part of follow up after his right parotid gland resection, an Aquilion ONE CT angiography was performed. Volume was scanned using a single 0.5 second rotation and 0.3 mSv of radiation dose without sedation. Without evidence of a recurrent or residual lesion, some small residual right parotid gland tissue is still present. *Image courtesy of Arkansas Children's Hospital.*

www.medical.toshiba.com

REFERENCES

1. Mettler FA, Wiest PW, Locken JA et al. 2000, CT scanning: patterns of use and dose. J Radiol Prot. 20:353-359.

2. Committee to Assess Health Risks from Exposure to Low Levels of Ionizing Radiation; Nuclear and Radiation Studies Board, Division on Earth and Life Studies, National Research Council of the National Academies. Health Risks From Exposure to Low Levels of Ionizing Radiation: BEIR VII Phase 2. Washington, DC: The National Academies Press; 2006.

3. Cravero JP, Blike GT, Beach M, Gallagher SM, Hertzog JH, Havidich JE, Gelman B; Pediatric Sedation Research Consortium. 2006, Incidence and nature of adverse events during pediatric sedation/anesthesia for procedures outside the operating room: report from the Pediatric Sedation Research Consortium. Pediatrics: 118(3):1087-96.

4. Dartmouth Pediatric Sedation Project Site. http://an.hitchcock.org/PediSedation. Accessed Jan 23, 2009.

5. The Alliance for Radiation Safety in Pediatric Imaging. Image Gently site. http://www.pedrad.org/associations/5364/ig. Accessed Jan 23, 2009.

Made for Life

TOSHIBA AMERICA MEDICAL SYSTEMS, INC.

2441 Michelle Drive, Tustin CA 92780 / 800.421.1968

CTWP1069US